

CASE REPORT

Rapid and long-lasting response to selpercatinib of paraneoplastic Cushing's syndrome in medullary thyroid carcinoma

Marine Sitbon¹, Porhuoy Chou², Seydou Bengaly², Brigitte Poirot³, Marie Laloi-Michelin⁴, Laure Deville¹, Atanas Pachev⁵, Ahouefa Kowo-Bille², Clement Dumont⁶ and Cécile N Chougnat²

¹Pharmacy Department, Hospital Saint-Louis AHP, Paris, France

²Endocrine Oncology Department, Saint-Louis Hospital (AP-HP), Université Paris Cité, Paris, France

³Department of Molecular Oncology, Saint-Louis Hospital (AP-HP), Université Paris Cité INSERM U 944, CNRS UMR 7212, Paris, France

⁴Department of Internal Medicine, Hospital Lariboisière AHP, Paris, France

⁵Radiology Department, Saint-Louis Hospital (AP-HP), Université Paris Cité, Paris, France

⁶Medical Oncology Department, Saint-Louis Hospital (AP-HP), Université Paris Cité, Paris, France

Correspondence should be addressed to C N Chougnat Email cecile.chougnat@aphp.fr

Abstract

The endocrine secretions of carcinomas can be life-threatening. Medullary thyroid carcinoma (MTC) is a rare cancer that is often associated with cortisol secretion, leading to paraneoplastic Cushing's syndrome. Mutations of the proto-oncogene RET are driver molecular events in 70% of MTC cases. Here, we report a case of a woman, born in 1956, who was diagnosed with sporadic MTC in 2005, with subsequent relapses treated with focal treatments. In April 2019, she presented with severe and rapidly progressive paraneoplastic Cushing's syndrome associated with lymph node, lung, liver and bone metastases. A supraclavicular lymph node biopsy revealed a somatic p.M918T (c.2753T>C) mutation in exon 16 of the RET proto-oncogene. The patient began treatment with selpercatinib in September 2019. Clinical efficacy was immediate. Chronic diarrhea disappeared within a few days. Clinical hypercorticism quickly disappeared, with quick improvements in muscle and skin conditions and fatigue. Two months after treatment initiation, urinary free cortisol normalized to 42 µg/24 h. Levels of the tumor markers carcinoembryonic antigen (CEA) and calcitonin also greatly decreased from baseline. After 34 months of treatment, selpercatinib elicits sustained clinical, biological and morphological responses. In summary, this case report illustrates the rapid and long-lasting antisecretory effect of selpercatinib associated with tumor control. As Cushing's syndrome associated with medullary thyroid cancer is associated with poor prognosis, this case report is very encouraging. In addition, this suggests the potential benefit of molecular testing in all cases of medullary thyroid cancer.

Key Words

- ▶ medullary thyroid cancer
- ▶ Selpercatinib
- ▶ Cushing's syndrome
- ▶ RET mutation

Established facts

- Paraneoplastic Cushing's syndrome is dangerous and can be life-threatening.
- There are few results regarding the efficacy of RET inhibitor treatment in medullary thyroid carcinoma (MTC) with RET mutation.

Novel insights

- Efficacy of selpercatinib in MTC-associated paraneoplastic Cushing's syndrome.
- Selpercatinib elicits a rapid and long-lasting response in RET-mutated MTC with bone metastases in the first line.

Introduction

The endocrine secretions of carcinomas can be life-threatening. Medullary thyroid carcinoma (MTC) is a rare cancer that is often responsible not only for hormone secretion, mainly calcitonin secretion, but also possibly adrenocorticotrophic hormone (ACTH) secretion, leading to paraneoplastic Cushing's syndrome.

Mutations of the proto-oncogene *RET* mutations are driver molecular events in 70% of MTC cases (1). More than half of sporadic MTC exhibit somatic *RET* mutation in tumor cells, and nearly all patients with familial MTC have a *RET* germline mutation (2). The gold-standard systemic treatment for metastatic MTC is vandetanib.

Numerous intratumoral *RET* mutations exist, leading to heterogeneous phenotypes in terms of aggressiveness (3). The recent development of RET-targeted therapies opens new therapeutic options for advanced *RET*-mutated MTC. In particular, selpercatinib (LOXO-292) is a highly selective ATP-competitive RET inhibitor, which has been shown to induce long-lasting responses in patients with *RET* intratumoral mutation MTC and RET fusion-positive differentiated thyroid cancers (1, 4). Here, we report a case of rapid and long-lasting resolution on selpercatinib of a paraneoplastic Cushing's syndrome associated with metastatic medullary thyroid cancer.

Case report/case presentation

A woman, born in 1956, was diagnosed with sporadic MTC in 2005, for which she underwent complete thyroidectomy with bilateral central compartment and lateral compartment neck dissection. Cervical recurrences were treated by two supplementary surgeries. Liver metastases, which were slowly progressing since 2008, were treated by radiofrequency ablation in 2015. Bone metastases, which were diagnosed in 2010, were treated by external beam radiotherapy in 2013 because of spinal cord compression, followed by denosumab 120 mg for 5 years. Denosumab was discontinued in December 2018 because of osteonecrosis of the jaw. As of 2019, the patient

had grade 2 chronic diarrhea for several years and bone pain, but she refused to be treated by vandetanib, fearing the cardiac side effects (prolongation of QT interval and torsade de pointes).

The patient was also treated in 2013 for multifocal invasive ductal breast carcinoma (maximum grade 2, pT2N0, estrogen and progesterone receptor-positive, Her2-positive, Ki67 20%) by surgery and adjuvant chemotherapy (epirubicin, cyclophosphamide, docetaxel, trastuzumab) and anastrozole (until February 2019).

In April 2019, she presented with severe and rapidly progressive paraneoplastic Cushing's syndrome. At the first endocrine oncology evaluation, the patient had Eastern Cooperative Oncology Group (ECOG) performance status of 2 and secretory syndrome: clinically hypercortisolism (asthenia, moon face, muscle weakness, fragile skin) and grade 3 diarrhea induced by high calcitonin levels.

A supra clavicular lymph node biopsy confirmed MTC progression and revealed a somatic p.M918T (c.2753T>C) mutation in exon 16 of the *RET* proto-oncogene in 2019. Due to the patient's poor condition, bilateral adrenalectomy was judged too dangerous. Emergency embolization of the right adrenal gland was performed in June 2019 to control life-threatening hypercorticism. The patient refused contralateral embolization, and Cushing's syndrome persisted. She was treated with oral ketoconazole for 1 month while waiting for selpercatinib treatment to be initiated. This treatment was delayed because of drug accessibility and traumatic femoral fracture.

Before the treatment, 24-h urinary free cortisol (UFC) excretion was found to be increased to 298 µg/24 h (six times the upper limit of normal values), with inadequate normal ACTH, confirming ACTH-dependant hypercorticism. Morphologically (on scanner and MRI), the patient had cervical and mediastinum enlarged lymph nodes, as well as lung, liver and bone metastases.

The patient began treatment with selpercatinib in September 2019. Initial dosage should have been 320 mg/day (160 mg BID), but the patient misunderstood and took only half of the dose (80 mg BID) for 3 months.

Despite underdosage, clinical efficacy was noticeable from the first month. Chronic diarrhea stopped only after few days. Clinical hypercorticism quickly disappeared, with quick improvements in muscle and skin conditions and decreased fatigue. Two months after treatment initiation, UFC was normalized to 42 $\mu\text{g}/24\text{ h}$. Levels of the serum tumor markers CEA and calcitonin also greatly decreased from baseline 950 $\mu\text{g}/\text{L}$ (183 \times ULN) and 36,257 pg/mL (3626 \times ULN) to 670 $\mu\text{g}/\text{L}$ (129 \times ULN) and 248 pg/mL (25 \times ULN), respectively.

As of June 2022, treatment with selpercatinib is still ongoing. Because the patient presented grade 2 fatigue at 320 mg/day dose, she has been treated at 240 mg/day since February 2020. The patient showed sustained clinical, biological and morphological responses.

Hepatic MRI performed in March 2022 showed a partial response of 50% per RECIST 1.1, with no new lesions and a significant decrease in the number and size of necrotic lesions. CT scan also shows persistent partial response of lung, liver and lymph node metastases. Bone metastases are stable. The patient has a normal quality of life, she has no diarrhea and is clinically in eucorticism. Tolerance of the treatment is good, as she only complains of grade 1 headache. She performs physical exercise five times a week. UFC values remain normal (shown in Fig. 1), and because of a trend toward biological hypocorticism, she takes hydrocortisone 10 mg per day. Levels of CEA and calcitonin remain low (shown in Fig. 2). Although the patient is no longer treated with any anti-osteoclastics, she has not had any skeletal-related events (SRE) since the introduction of selpercatinib.

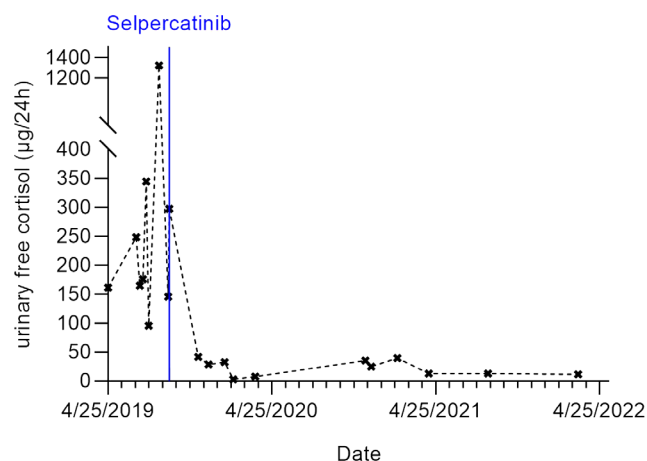


Figure 1
Urinary free cortisol levels at the time of diagnosis and their outcome after selpercatinib oral treatment.

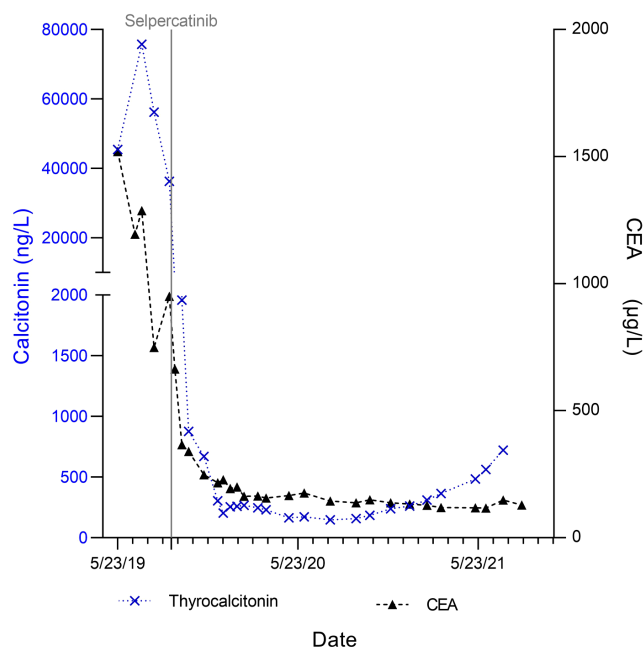


Figure 2
Changes in serum tumor markers: calcitonin and CEA levels at the time of diagnosis and their outcome after selpercatinib oral treatment.

Discussion/conclusion

Cushing's syndrome is a rare complication of MTC induced by ectopic ACTH secretion (5). Severe hypercortisolism is life-threatening, and the short-term vital prognosis is very poor, mostly because of pulmonary embolism and infections, underlining the necessity of hormonal control. Cortisol secretion inhibitors such as ketoconazole, metyrapone or mitotane are effective in reducing hypercortisolemia (6), but their effects are partial and therapeutic escape occurs (7). Furthermore, many side effects limit their use, and they are not effective on diarrhea and have no antitumor activity. Moreover, these treatments induce problematic cytochrome-related drug–drug interactions. Other therapeutic options are surgical bilateral adrenalectomy or local radiological procedures, such as cryotherapy, radiofrequency or embolization, but these lead to definitive and complete adrenal insufficiency and require anesthesia, which is problematic due to patients' often poor medical condition. The benefit of tyrosine kinase inhibitor in the reversal of MTC Cushing's syndrome has been previously published. Long-term (more than 3 years) reversal of MTC Cushing by vandetanib has already been shown (8, 9), but the patient refused vandetanib treatment. Similarly, another team showed a rapid response with sorafenib, but sorafenib was not approved for MTC (10).

Here, we report successful treatment of Cushing's syndrome with RET-targeted therapy in a patient with *RET*-mutated MTC. The patient experienced a rapid and long-lasting tumor response to selpercatinib associated with dramatic antiseecretory action concerning both ACTH and calcitonin, even at a reduced dosage. Resolution of calcitonin-induced diarrhea was also a significant benefit from selpercatinib treatment since it impairs quality of life and may be dangerous due to electrolyte loss and undernutrition. This is more satisfactory when considering the high metastatic volume and the mutation of codon 918 in the *RET* proto-oncogene, which is associated with poor outcome in sporadic MTC (11).

Morphological response was observed in our patient with RECIST 1.1 partial response, with a volumetric decrease of cervical adenopathy and liver metastases and stability of lung metastases. This is consistent with a previous selpercatinib study, in which an objective response rate (ORR) of 73% (95% CI, 62–82) and a 1-year PFS of 92% (95% CI, 82–97) were reported in patients with RET-mutant MTC without previous treatment by vandetanib or cabozantinib (1). Selpercatinib treatment is now approved by the U.S. Food and Drug Administration in patients with advanced or metastatic RET-mutant MTC (12). The other anti-RET praseltinib (13) seems to be promising in MTC, but it was not available outside clinical research in 2019.

Assessment of bone metastasis response to treatment is challenging. In our patient's case, the absence of SRE such as new bone metastatic lesions on MRI, pathological bone fracture, spinal cord compression or bone-related orthopedic surgical intervention for 2 years is a very satisfactory outcome. SREs may be favored by Cushing's syndrome, and they impair patients' quality of life and functionality. Systemic anti-tumoral treatment is often poorly effective in the prevention of SRE in thyroid cancer (14).

Forde *et al.* reported a similar dramatic clinical and biochemical response to selpercatinib even after 18 months of treatment with vandetanib (15). Our case report illustrates response to selpercatinib in vandetanib-naïve patients. The latest MTC guidelines suggest the benefit of molecular testing in all MTC cases (16), paving the way toward upfront-targeted treatment with RET-targeted agents.

In addition, our case report illustrates the favorable toxicity profile of selpercatinib.

In summary, this case report shows the rapid and long-lasting antisecretory effect of selpercatinib associated with tumor control. It illustrates the benefit of molecular testing in all cases of metastatic MTC and

suggests the place of RET-targeted agents as a choice therapeutic option for patients with *RET*-mutated MTC with endocrine paraneoplastic syndromes, including Cushing's syndrome.

Declaration of interest

The authors declare that there is no conflict of interest that could be perceived as prejudicing the impartiality of this case report.

Funding

Selpercatinib was provided by Loxo Oncology, Inc., a wholly owned subsidiary of Eli Lilly and Company during the Named Patient Program, use basis for the treatment of locally advanced or metastatic solid tumors with RET activation.

Statement of ethics

The patient provided written informed consent for this case report.

Author contribution statement

Marine Sitbon: wrote the paper with input from all authors and designed the figures. Porhuoy Chou: collected the data. Seydou Bengaly: collected the data. Brigitte Poirot: contributed to the analysis and the interpretation of the results. Marie Laloi-Michelin: contributed to the analysis and the interpretation of the results. Laure Deville: proofreading. Ahouefa Kowo-Bille: collected the data. Atanas Pachev: radiological evaluation. Clement Dumont: proofreading. Cécile N Chougnet: contributed to the interpretation of the result, the writing of the manuscript and supervised the project. All authors discussed the results and contributed to the final manuscript.

References

- 1 Wirth LJ, Sherman E, Robinson B, Solomon B, Kang H, Lorch J, Worden F, Brose M, Patel J, Leboulleux S, *et al.* Efficacy of selpercatinib in *RET*-altered thyroid cancers. *New England Journal of Medicine* 2020 **383** 825–835. (<https://doi.org/10.1056/NEJMoa2005651>)
- 2 Wells SA, Asa SL, Dralle H, Elisei R, Evans DB, Gagel RF, Lee N, Machens A, Moley JF, Pacini F, *et al.* Revised American Thyroid Association guidelines for the management of medullary thyroid carcinoma. *Thyroid* 2015 **25** 567–610. (<https://doi.org/10.1089/thy.2014.0335>)
- 3 Lorusso L, Cappagli V, Valerio L, Giani C, Viola D, Puleo L, Gambale C, Minaldi E, Campopiano MC, Matrone A, *et al.* Thyroid cancers: from surgery to current and future systemic therapies through their molecular identities. *International Journal of Molecular Sciences* 2021 **22** 3117. (<https://doi.org/10.3390/ijms22063117>)
- 4 Andreev-Drakhlin A, Cabanillas M, Amini B & Subbiah V. Systemic and CNS activity of selective RET inhibition with selpercatinib (LOXO-292) in a patient with RET-mutant medullary thyroid cancer with extensive CNS metastases. *JCO Precision Oncology* 2020 **4** PO.20.00096. (<https://doi.org/10.1200/PO.20.00096>)
- 5 Wijewardene AA, Glastras SJ, Learoyd DL, Robinson BG & Tsang VHM. ACTH-secreting medullary thyroid cancer: a case series. *Endocrinology*,

- Diabetes and Metabolism Case Reports* 2017 **2017** 16-0110. (<https://doi.org/10.1530/EDM-16-0110>)
- 6 Corcuff JB, Young J, Masquefa-Giraud P, Chanson P, Baudin E & Tabarin A. Rapid control of severe neoplastic hypercortisolism with metyrapone and ketoconazole. *European Journal of Endocrinology* 2015 **172** 473–481. (<https://doi.org/10.1530/EJE-14-0913>)
 - 7 Castinetti F, Guignat L, Giraud P, Muller M, Kamenicky P, Drui D, Caron P, Luca F, Donadille B, Vantyghem MC, et al. Ketoconazole in Cushing's disease: is it worth a try? *Journal of Clinical Endocrinology and Metabolism* 2014 **99** 1623–1630. (<https://doi.org/10.1210/jc.2013-3628>)
 - 8 Paepegaey AC, Cochand-Priollet B, Louiset E, Sarfati PO, Alifano M, Burnichon N, Bienvenu-Perrard M, Lahlou N, Bricaire L & Groussin L. Long-term control of hypercortisolism by vandetanib in a case of medullary thyroid carcinoma with a somatic RET mutation. *Thyroid* 2017 **27** 587–590. (<https://doi.org/10.1089/thy.2016.0334>)
 - 9 Baudry C, Paepegaey AC & Groussin L. Reversal of Cushing's syndrome by vandetanib in medullary thyroid carcinoma. *New England Journal of Medicine* 2013 **369** 584–586. (<https://doi.org/10.1056/NEJMc1301428>)
 - 10 Barroso-Sousa R, Lerario AM, Evangelista J, Papadia C, Lourenço DM, Lin CS, Kulcsar MA, Fragoso MC & Hoff AO. Complete resolution of hypercortisolism with sorafenib in a patient with advanced medullary thyroid carcinoma and ectopic ACTH (adrenocorticotropic hormone) syndrome. *Thyroid* 2014 **24** 1062–1066. (<https://doi.org/10.1089/thy.2013.0571>)
 - 11 Zedenius J, Larsson C, Bergholm U, Bovée J, Svensson A, Hallengren B, Grimelius L, Bäckdahl M, Weber G & Wallin G. Mutations of codon 918 in the RET proto-oncogene correlate to poor prognosis in sporadic medullary thyroid carcinomas. *Journal of Clinical Endocrinology and Metabolism* 1995 **80** 3088–3090. (<https://doi.org/10.1210/jcem.80.10.7559902>)
 - 12 Bradford D, Larkins E, Mushti SL, Rodriguez L, Skinner AM, Helms WS, Price LSL, Zirkelbach JF, Li Y, Liu J, et al. FDA approval summary: selipercatinib for the treatment of lung and thyroid cancers with RET gene mutations or fusions. *Clinical Cancer Research* 2021 **27** 2130–2135. (<https://doi.org/10.1158/1078-0432.CCR-20-3558>)
 - 13 Subbiah V, Hu MI, Wirth LJ, Schuler M, Mansfield AS, Curigliano G, Brose MS, Zhu VW, Leboulleux S, Bowles DW, et al. Pralsetinib for patients with advanced or metastatic RET-altered thyroid cancer (ARROW): a multi-cohort, open-label, registrational, phase 1/2 study. *Lancet: Diabetes and Endocrinology* 2021 **9** 491–501. ([https://doi.org/10.1016/S2213-8587\(21\)00120-0](https://doi.org/10.1016/S2213-8587(21)00120-0))
 - 14 Iñiguez-Ariza NM, Bible KC & Clarke BL. Bone metastases in thyroid cancer. *Journal of Bone Oncology* 2020 **21** 100282. (<https://doi.org/10.1016/j.jbo.2020.100282>)
 - 15 Forde HE, Mehigan-Farrelly N, Ryan K, Moran T, Grealley M, Duffy AG & Byrne MM. Metastatic medullary thyroid carcinoma presenting as ectopic Cushing's syndrome. *Endocrinology, Diabetes and Metabolism Case Reports* 2021 **2021** EDM200207. (<https://doi.org/10.1530/EDM-20-0207>)
 - 16 Kim M & Kim BH. Current guidelines for management of medullary thyroid carcinoma. *Endocrinology and Metabolism* 2021 **36** 514–524. (<https://doi.org/10.3803/EnM.2021.1082>)

Received in final form 28 June 2022

Accepted 6 September 2022

Accepted Manuscript published online 7 September 2022

