

RESEARCH

Diagnostic utility of repeat fine needle aspirations of benign thyroid nodules

Rachelle P Mendoza¹, Richard Cody Simon², Nicole A Cipriani² and Tatjana Antic²¹Department of Pathology, University of Rochester Medical Center, Rochester, New York, USA²Department of Pathology, University of Chicago, Chicago, Illinois, USACorrespondence should be addressed to R Mendoza: Rachelle_Mendoza@URMC.Rochester.edu

Abstract

Objective: This study aims to analyze the diagnostic utility of multiple repeat FNA on thyroid nodules with initially benign diagnosis.

Methods: In a 5-year period, 1658 thyroid nodules with initially benign FNAs were retrospectively reviewed and followed for subsequent resection and repeat biopsy.

Results: Out of 2150 thyroid nodules, 1658 (77.1%) were diagnosed as benign on FNAs. The average age at diagnosis was 57.4 years (range: 11–93 years), and most were females (83.8%). Repeat FNA was performed on 183 benign nodules, of which 141 (8.5%) were sampled a second time and 42 (2.5%) had two or more repeat samplings. For the benign nodules without repeat FNAs, 124 had benign resection. Of cases with one-time repeat FNA, most ($n = 101$) remained benign on repeat FNAs, 13 of which were benign on resection. Eleven had atypical repeat FNAs, five were resected, four of which were benign and one was atypical follicular neoplasm with *HRAS* and *TERT* promoter mutations. Of cases with multiple repeat FNA, most ($n = 35$) were still benign on repeat FNAs, one had benign resection. Two had atypical repeat biopsies, one was PTC on resection with *CCD6::RET* fusion. The positive predictive value significantly decreased from 41.1% on single FNA to 8.3% on one-time repeat ($P < 0.001$) and 16.7% on multiple repeat ($P = 0.002$). The total cost for the work-up of previously benign nodules was \$285,454.

Conclusions: Repeat FNA biopsies did not provide an additional diagnostic value in the evaluation of benign thyroid nodules, and often led to unwarranted follow-up procedures and significantly increased health-care cost.

Keywords: thyroid; thyroid nodule; aspiration biopsy; fine needle aspiration

Introduction

Fine needle aspiration cytology (FNA) is widely accepted as the most accurate and cost-effective diagnostic procedure in the assessment of thyroid nodules. The Bethesda System outlines the diagnostic categories for thyroid nodules, along with recommended follow-up management based on risk of malignancy (1). A large majority (65–75%) of thyroid nodules are benign (2);

however, several studies have confirmed a minor yet nonnegligible 1–10% risk of a false-negative cytologic diagnosis (2, 3, 4). This is the main basis for the continued follow-up of cytologically benign nodules. Although there is a clear algorithm following atypical and higher Bethesda categories, there is no consensus on the optimal regimen for benign thyroid nodules.

Clinical practices have ranged from ultrasound monitoring to repeat FNA. Flanagan *et al.* studied 70 patients with two or more repeat FNA after an initial benign result and then subsequently underwent surgical management (5). The repeat FNA was able to identify malignancy in 2 out of 70 patients, while 7 of 17 indeterminate repeat FNA results had malignant final pathology diagnosis. They concluded that the use of one repeat FNA increased the sensitivity for malignancy from 81.7% to 90.4% and decreased the false-negative rate from 17.1% to 11.4%. With more than one repeat FNA, there was no improvement in performance characteristics. Another study showed that repeating FNA did not decrease the rate of benign cytology reports and the agreement between first and second FNA was significantly high (6). About 15% of their patients with benign first and second FNAs had a resection pathology of a thyroid malignancy, and 14% had incidental microcarcinoma, both rates were similar to benign nodules with single FNA. The combined recommendation for these studies was to follow up initially benign nodule with ultrasound risk stratification and overall clinical picture, which may be more beneficial than a repeat FNA.

The present study aims to establish the diagnostic value and cost-benefit utility of repeat FNA on benign thyroid nodules by evaluating a large sample size of thyroid nodules.

Materials and methods

Selection of cases

All thyroid FNAs performed at the University of Chicago within a 5-year period were retrospectively reviewed. All cases with benign FNAs were included and followed for up to 5 years for any subsequent repeat FNA. Clinical follow-up of thyroid nodules with repeat FNAs was obtained from the electronic medical record. Imaging analysis (MRI, CT scan, and/or ultrasound) was reviewed along with clinical examination to ensure that the same nodule was sampled. If resected, the status of the final nodule (benign versus nonbenign) was recorded, as well as the presence of incidental papillary thyroid microcarcinoma (PTmC) in the background. The presence of incidental PTmC was considered under 'benign' on resection as this area may not have been sampled during the FNA procedure. Molecular analysis, if performed, was documented. There was no noninvasive follicular thyroid neoplasm with papillary-like nuclear features (NIFTP) identified in this cohort. The study was approved by the University of Chicago Institutional Review Board (IRB22-1207).

The cytologic diagnosis of all thyroid nodules was performed by an experienced cytopathologist. Benign and atypical diagnoses was made based on the

diagnostic criteria stated in the Bethesda System 2009 (1).

Institutional criteria for thyroid nodule FNA

The institutional criteria for a repeat FNA are based on the 2015 American Thyroid Association (ATA) guidelines, which combine sonographic patterns and size of nodule (7). If the sonographic pattern is benign, no repeat FNA should be considered. When there is very low suspicion of possible thyroid malignancy based on sonographic patterns, FNA will be done if the nodule measures 2 cm or larger, but observation may also be an alternative option. When there is low suspicion of malignancy, FNA is recommended if the nodule is at least 1.5 cm in size, and when there is intermediate to high suspicion, FNA must be performed if the nodule size is at least 1 cm. Suspicion of malignancy is based on the presence of any of the following sonographic features: solid, hypoechoic nodule, irregular margins (infiltrative, microlobulated), microcalcifications, taller than wide shape, rim calcifications with small extrusive soft tissue component, and evidence of extrathyroidal extension. The presence of microcalcifications, rim calcifications, and/or irregular margins makes the nodule high suspicion.

Statistical analysis

Statistical analysis was performed using IBM SPSS version 29. Cohen's kappa was computed to assess agreement between initial and repeat FNA results. Positive (PPV) and negative predictive values (NPV) were calculated based on resection results (incidental PTmC was considered benign) and compared using one-way ANOVA with Bonferroni correction for multiple testing. *P* values less than 0.05 were considered statistically significant. Cost analysis was performed using third-party payer estimation.

Results

A total of 2150 thyroid nodules underwent FNA from January 1, 2016, to December 30, 2020, the large majority of which ($n=1658$, 77.1%) were benign (Fig. 1). All 1658 benign thyroid nodules from 1290 patients were followed for subsequent biopsy and/or resection. The average age at initial biopsy was 57.4 years (range 11–93 years) and most were females ($n=1388$, 83.8%). Out of the 1658 thyroid nodules with benign FNAs, most cases ($n=1474$, 88.9%) did not have a subsequent FNA after an average follow-up period of 48.9 months (range 0.1–262.2). A large majority of these single FNAs ($n=1350/1474$, 91.6%) were monitored clinically and radiologically. A subset of

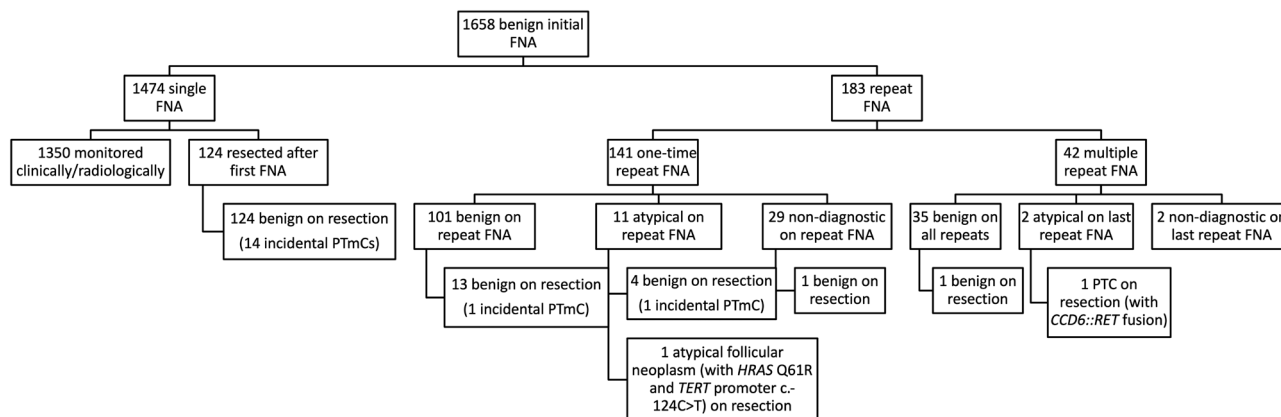


Figure 1

Diagram of the subsequent fine needle aspiration cytology and resection diagnosis of benign thyroid nodules followed in a 5-year period.

cases was resected ($n=124/1474$; 8.4%). All nodules of interest were benign, and 14 (0.9%) had incidental PTmC, which ranged in size from <0.01 cm to 0.6 cm (average of 0.3 cm). Table 1 summarizes the clinical and follow-up information of these nodules. The incidence rate of a nonbenign final diagnosis in these nodules with single FNA was 0% (Table 2).

A minority of initially benign thyroid nodules ($n=183$, 11%) underwent repeat FNAs, 141 (8.5%) of which had one repeat FNA and 42 (2.5%) of which had more than one repeat FNAs. The one-time repeat FNA performed on 141 initially benign thyroid nodules was prompted by nodule enlargement ($n=63$), worrisome change in ultrasonographic morphology ($n=12$), or as routine follow up ($n=66$) (Table 2). Nodule enlargement of at least 0.2 cm in any dimension was an indication for repeat sampling, and the median size difference from original to repeat ultrasound was 0.6 cm (range: 0.2–0.5 cm). The average interval between the initial and repeat FNAs was 28.6 months (range: 0.1–60.0). Out of these 141 benign nodules with second FNAs, 101 (71.6%) remained to be benign (Cohen’s kappa 0.7; Fig. 2). Thirteen of these repeat benign nodules had subsequent resection. All nodules of interest were benign, and one revealed incidental PTmC (0.1 cm). Eleven (7.8%) nodules were atypical on the second FNA, 5 of which underwent resection. Four nodules had benign resection pathology (of which one had two incidental PTmCs, measuring 0.1 and 0.8 cm), and one nodule was diagnosed as a noninvasive atypical follicular neoplasm with *HRAS* (Q61R) and *TERT* promoter (c.-124C>T) mutations (Fig. 3). The incidence rate of a nonbenign final diagnosis in these nodules with one-time repeat FNA was 0.7% (Table 2).

A small subset of benign thyroid nodules underwent two or more repeat FNAs ($n=42$, 2.5%). Most nodules ($n=31$) had two repeat FNAs, nine had three repeat sampling, and two nodules were sampled repeatedly four times. Multiple repeat FNAs were performed

due to increase in size of the nodules ($n=24$), change in imaging morphology ($n=4$), as part of routine follow-up ($n=12$), or per patient request ($n=2$). The median increase in size of nodules was 0.7 cm (range: 0.2–2.1). The average interval between repeat samplings was 52.9 months (range: 0.3–60.0). Most ($n=35$, 83.3%) were still benign on all subsequent FNAs (Cohen’s kappa 0.8; Fig. 3). One was resected and had a benign final diagnosis. Two were atypical on repeat FNA. One was resected, showed a *CCDC6::RET* fusion on molecular analysis of FFPE tissue, and was diagnosed as papillary thyroid carcinoma (Fig. 3). The malignancy rate for multiple repeat benign thyroid FNA was 2.4% (Table 2).

The rate of atypical FNA diagnosis in clinically and/or histologically benign thyroid nodules were 90.9% and 83.3% in one-time (total of two benign thyroid FNA diagnoses) and multiple repeat FNAs (total of more than two benign thyroid FNA diagnoses), respectively. The negative predictive value (NPV) of thyroid FNA remained at 100% on one-time and multiple repeat biopsy, similar to the 100% NPV of single benign FNA ($P=1.000$). The positive predictive value (PPV) significantly decreased from 41.1% on single FNA to 8.3% on one-time ($P < 0.001$) and 16.7% on multiple repeat biopsies ($P=0.002$). The relative risk (RR) of getting a benign resection diagnosis after a benign FNA did not differ significantly ($P=0.495$) between single and repeat biopsies. Similarly, the RR difference between one-time and multiple repeat FNAs also did not have a statistical significance ($P=0.347$).

With the average cost for FNA being \$349, the total cost for repeat FNAs was \$63,867 (Table 3). The cost of molecular testing was \$3808 per specimen and resulted in a total cost of \$30,464. The cost analysis of a false-negative resulting in a thyroidectomy resulted in an average of \$9101 per case with an upper limit of \$20,818 given major complications or comorbidities. This resulted in a conservative surgical cost estimate of \$154,719 for the diagnostic lobectomies

Table 1 Clinical and follow-up data of benign thyroid nodules based on the number of FNA sampling. Data are presented as *n* (%).

Number of FNA	<i>n</i>	Sex		Location of nodule			Repeat FNA result			Resection diagnosis	
		F	M	Right	Left	Isthmus	ND	Benign	Atypical	Benign	Nonbenign
Single	1474	1237 (83.9)	237 (16.1)	669 (45.4)	671 (45.5)	134 (9.1)	–	–	–	124 (8.4)	0 (0.0)
1 repeat	141	110 (78.0)	31 (22.0)	67 (47.5)	61 (43.3)	13 (9.2)	29 (20.6)	101 (71.6)	11 (7.8)	18 (12.8)	1 (0.7)
>2 repeat	42	41 (97.6)	1 (2.4)	21 (50.0)	18 (42.9)	3 (7.1)	2 (4.8)	35 (83.3)	5 (11.9)	1 (2.4)	1 (2.4)

^aValues are median (range).

F, female; FNA, fine needle aspiration; M, male; ND, nondiagnostic.

Table 2 Diagnostic characteristics of one-time and repeat sampling of benign thyroid nodules.

Number of FNA	<i>n</i>	Interval between repeats, ^a months	Reason for repeat FNA, <i>n</i> (%)			NBR, %	NPV, %	PPV, %	RR (95% CI)
			Increase in size	Change in morphology	Patient driven				
Single	1474	–	–	–	–	0.0	100.0	41.1	1.1 (1.0–1.3)
1 repeat	141	28.6 (0.1–60.0)	63 (44.7)	12 (8.5)	0 (0.0)	0.7 (0.2–5.0)	100.0	8.3	1.3 (0.8–1.9)
>2 repeat	42	52.9 (0.3–60.0)	24 (57.1)	4 (9.5)	2 (4.8)	0.7 (0.2–2.1)	100.0	16.7	1.2 (0.9–1.6)

^aValues are median (range).

FNA, fine needle aspiration; NBR, nonbenign rate; NPV, negative predictive value; PPV, positive predictive value; RR, risk ratio.

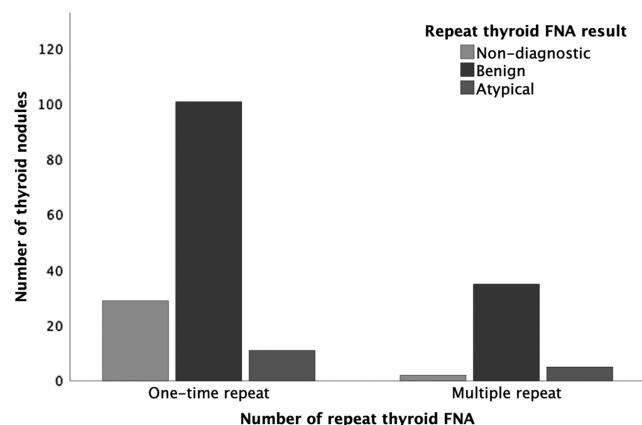


Figure 2

Bar graph of the subsequent fine needle aspiration (FNA) of initially benign thyroid FNA. This figure shows the proportion of subsequent thyroid FNA diagnosis in patients with one repeat FNA and those with 2 or more repeat FNAs. Out of the 141 benign nodules with second FNAs, 101 (71.6%) remained to be benign and 11 (7.8%) nodules were atypical (Cohen's kappa 0.7). Out of the 42 nodules with two or more repeat benign FNAs, 35 (83.3%) were still benign and 2 (4.8%) had atypical cytology (Cohen's kappa 0.8).

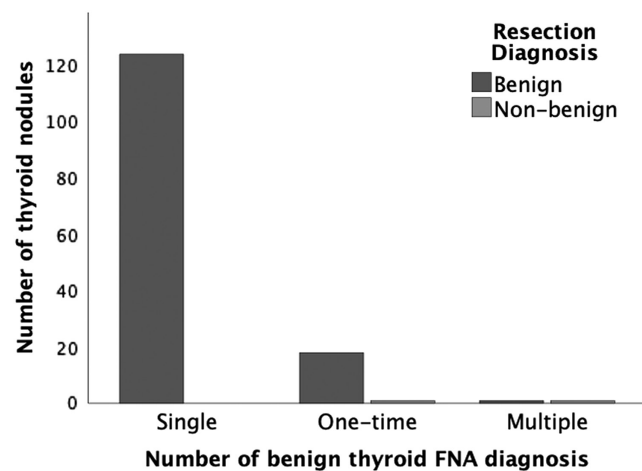


Figure 3

Bar graph of the resection diagnosis of initially benign thyroid nodules based on the number of repeat thyroid FNA. This figure shows the resection diagnosis of thyroid nodules with single benign FNA, one repeat benign FNA, and 2 or more benign FNA. Out of the 1474 nodules with single benign FNAC, 124 were resected and all were benign (14 with incidental papillary thyroid microcarcinoma, PTmC). Out of the 141 benign nodules with second FNAs, 13 with second benign FNA all had subsequent benign resection diagnosis (one incidental PTmC), while 4 of 5 resected nodules with atypical second FNA had benign nodules on resection, and one was a noninvasive atypical follicular neoplasm. Out of the 42 benign nodules with multiple repeat biopsies, one with multiple benign FNAs was still benign on resection, while one of those with final atypical FNA was papillary thyroid carcinoma on resection.

Table 3 Cost analysis of thyroid nodule FNA.

Description	Number	Cost	Subtotal cost
FNA repeat			\$63,867
One-time	141	\$49,209	
Multiple	42	\$14,658	
Underwent molecular	8	\$30,464	\$30,464
Underwent DL and			\$191,123
Benign	17	\$154,719	
Malignant	4	\$36,404	
Total cost			\$285,454

DL, diagnostic lobectomy; PFNA, fine needle aspiration.

that resulted in benign nodules, and \$36,404 of surgical costs based on malignant nodules. The total cost for the work-up of previously benign nodules was \$285,454 to identify one PTC and one atypical follicular nodule.

Discussion

The increasing use and sensitivity of imaging modalities have led to a dramatic increase in the detection of thyroid nodules. Historically, the incidence of palpable thyroid nodules was approximately 4–7% (8), while in recent years, the incidence rate of thyroid nodules ranges from 19% to 68% using high sensitivity imaging such as high frequency ultrasound examination (3, 9, 10, 11). Most of these thyroid nodules were in women and elderly, commonly detected incidentally during work up for other conditions (3, 11, 12, 13). In this study, we specifically followed benign thyroid nodules and determined the incidence rate of repeat FNA, the result of subsequent FNAs and resection diagnoses. After evaluating over 1600 thyroid nodules, our results showed that most benign thyroid nodules did not undergo repeat biopsy sampling. However, 11% of benign thyroid nodules underwent repeat FNAs, of which 23% had multiple (i.e. more than two) repeat samplings. Excluding incidental PTmCs in the background thyroid, only one carcinoma and one atypical follicular neoplasm were identified (representing a nonbenign incidence rate of <0.1% of all 1658 nodules and 1% of 183 nodules with repeat FNA). Although the nonbenign rate increased from 0% (in cases with single benign FNA) to 0.7% and 2.4% in one-time and multiple repeat FNAs, respectively, this malignancy rate remains within the expected malignancy risk following a benign FNA result, which ranges from 0% to 3% (14).

Most of the repeat samplings of benign thyroid nodules in the present cohort were due to increase in nodule size. The institutional criterion for recommending repeat biopsy was an increase in size of at least 0.2 cm in any dimension. The thyroid nodules with repeat FNA due to enlargement had a median increase in size of 0.6 cm (range: 0.2–5.0 cm)

and 0.7 cm (range: 0.2–2.1 cm) for one-time and multiple repeat sampling, respectively. In 2015, the American Thyroid Association (ATA) guidelines recommend that nodules with high-risk ultrasound characteristics should undergo repeat ultrasound and FNA within 12 months (7). Thyroid nodules with low to intermediate risk on ultrasound patterns must have repeat ultrasound in 12–24 months and repeat FNA if there is more than 50% increase in nodule volume. Nodules with very low risk ultrasound features do not require any follow-up but may be considered only after 24 months of initial detection. A study by Mohammadi *et al.* on 733 benign thyroid nodules revealed that 35% of these nodules unnecessarily underwent repeat FNA when applying the 2015 ATA criteria (15). While the malignancy rate in their study is comparable to the present cohort (1.2% vs 1.0%), the performance of repeat FNA was lower in the present study (183/1658, 11.0%), revealing a wide range of variation in the application of the ATA criteria for follow up. A study by Ajmal *et al.* showed that the rate of repeat FNA of initially benign thyroid nodules was 41.3% in their cohort, over a median follow-up time of 3 years (16). Most of these nodules were repeatedly sampled due to increase in size (mean increase of 7 mm); however, they found no significant difference in the nodule growth that occurred in malignant and benign nodules over time (16). These variations in the rate of repeat sampling may be largely due to the lack of consensus on the degree of nodule growth that should require a repeat biopsy. Some groups recommend re-biopsy when there is a 15% increase in nodule volume; others recommend using an increase in diameter as the trigger for repeat biopsy. In the current ATA guidelines, the authors suggest using a 20% increase in nodule diameter, with a minimum increase in 2 or more dimensions of at least 2 mm (7). In their cohort of 1819 cytologically benign thyroid nodules, Medici and colleagues observed that nodule growth led to a higher risk of repeat FNA as well as thyroidectomy, but not an increased risk of malignancy (17). In their study, the growth rates of the nodules that turned out to be histologically malignant did not differ from the growth rates of the benign nodules, with average increases of 119.5% (± 45.8) for the malignant and 108.5% (± 10.3) for the benign nodules ($P=0.820$) (17). The same study also identified determinants of nodule growth, which included solid parenchyma and younger age at diagnosis (<50 years), two groups of cases that can benefit from shorter follow-up interval than what they generally recommended (at least 3 years) (17). A similar finding was shown by Cavallo *et al.* in their study of 1003 thyroid nodules, revealing that thyroid nodule size is in fact inversely related to malignancy risk (4).

In the present study, a single repeat FNA of benign thyroid nodules did not result to an improvement of true negative rate and NPV. The NPV of a benign FNA

remained at 100% for both one-time and multiple repeats. The cost-effectiveness of multiple repeat tissue sampling approach may be in question when the resulting NPV is either lower or the same as a single benign FNA. This finding was in contrast with the observations of Oertel *et al.* in their study of over 10,000 thyroid nodules (18). Their results showed that the probability of a benign nodule on resection diagnosis increased from 90% after one benign FNA to 98% when confirmed by repeat aspiration (18), which became the basis of the authors' recommendation to routinely perform repeat FNA biopsy of thyroid nodules (18). However, this study failed to compare other diagnostic parameters. Our results showed that there was a significant decrease in the diagnostic performance (i.e. decreased PPV) when repeat FNA was performed on initially benign thyroid nodules, consequently leading to unwarranted follow-up procedures including molecular analysis, another repeat FNA with decreased interval, or resection.

The Bethesda System recommends repeat thyroid aspirations to be performed at least 3 months following the initial aspiration to prevent false-positive misinterpretations due to reactive/reparative changes (1). In this study, the median interval of repeat sampling was 28.6 months (range: 0.1–60.0) and 52.9 months (range: 0.3–60.0) for one-time and multiple repeat FNAs, respectively. According to the study by Ajmal *et al.*, the average time to diagnosis of cancer in patients with false-negative FNA biopsies was more than 4 years (16). After observing that repeat FNA on initially benign thyroid nodules lacked sensitivity, the authors recommended a conservative follow-up of ultrasound 1 year after the initial benign biopsy, and subsequent ultrasound every 2 or 3 years for a period of 5–10 years (16). They concluded that annual ultrasound was unnecessary in cases where the 1-year ultrasound did not show significant growth of ≥ 3 mm in any dimension and there was absence of highly concerning ultrasound procedures. In the present study, some repeat sampling was recommended by the surveillance radiologists even in the absence of increased nodule size and concerning morphologic changes. This further underscores the need to adapt an interdisciplinary approach in establishing recommendations for monitoring and evaluating initially benign thyroid nodules. The frequency of ultrasound follow-up dictates the occurrence of repeat sampling, and increasing the interval of ultrasound follow-up can potentially lead to better diagnostic yield of subsequent FNA, should it become clinically indicated.

Molecular analysis performed on subsequent atypical FNAs revealed genomic alterations linked to increased risk of malignancy in a few thyroid nodules included in this cohort. While molecular testing helps improve the preoperative cancer risk assessment of cytologically indeterminate thyroid nodules, it also contributes significantly to the cost of unnecessary

repeat FNAs (20). One nodule with atypical cytology harbored combined alterations in *HRAS* and *TERT*, with the subsequent resection diagnosis showing an atypical follicular neoplasm without evidence of invasion. Although this combined molecular finding has been prevalent in aggressive thyroid cancers (20, 21, 22), this nodule had a resection diagnosis of noninvasive follicular neoplasm and the patient remained recurrence free after a follow-up period of 48 months post thyroidectomy. Increasing reports of significant molecular alterations have been reported in follicular adenomas (23, 24), warranting further investigation on the clinical significance of these genomic findings in the evaluation and progression of cytologically and histologically benign thyroid nodules.

The common occurrence of repeat aspiration sampling of benign thyroid nodules naturally leads to a discussion on the cost-effectiveness of this approach. Subsequent nondiagnostic FNAs would be followed by another repeat FNA within 12 months, while atypical FNAs will be followed either by molecular analysis, repeat sampling, or resection. Hence, the cost of repeat FNAs should not be considered in isolation, but in conjunction with indicated follow-up procedures. Increased atypical rates in the repeat FNAs required molecular analysis and resection, most of which remained benign in the current cohort. Unwarranted follow-up procedures on benign thyroid nodules can cost thousands of dollars in health-care cost, without providing a diagnostic advantage. In contrast, repeat FNA is a cost-effective for indeterminate thyroid nodules (i.e. AUS/FLUS) when compared to diagnostic lobectomies (25). The cost-effective follow-up for benign thyroid nodule remains to be ultrasound and clinical surveillance (26), but even routine follow-up ultrasound is no longer recommended in older patients (27) and beyond 10 years of surveillance (16).

While the strength of this study includes the large sample size and long follow-up periods, there are certain limitations as well. Since the overall rate of malignancy in the thyroid nodules with benign FNA was relatively low in this cohort, the interpretation of PPVs in this context is limited. The initial ultrasound findings of the nodules prompting the first FNA were not available in the institutional electronic medical record for most patients since most of them were referred from multiple community clinics. Additional studies are warranted to investigate the correlation of the initial ultrasound findings and subsequent benign thyroid cytology.

In summary, repeating FNA biopsies of thyroid nodules based mostly on increase in nodule size and as a routine follow-up procedure did not provide additional diagnostic value in the evaluation of benign thyroid nodules. The risk of malignancy following a benign thyroid FNA remained to be within the expected value of 0% to 3% regardless of the number of repeat biopsies. The NPV remained the same while the PPV significantly decreased between single FNAs and repeat

FNAs, leading to increased health-care cost without diagnostic advantage. Repeat FNA is therefore not recommended as a routine follow-up of benign thyroid nodules in the absence of strong radiologic and clinical indications.

Declaration of interest

The authors declare that there is no conflict of interest that could be perceived as prejudicing the impartiality of the study reported.

Funding

This research did not receive any specific grant from any funding agency in the public, commercial, or not-for-profit sector.

Author contribution statement

RPM: methodology (lead), data curation (supporting), investigation (equal), formal analysis (lead), visualization, writing – original draft (lead). RCS: methodology (supporting), data curation (supporting), formal analysis (supporting). NAC: conceptualization (supporting), investigation (equal), data curation (supporting), writing – reviewing and editing (equal). TA: conceptualization (lead), investigation (equal), data curation (lead), supervision, writing – reviewing and editing (equal).

Acknowledgement

The authors would like to extend their sincerest gratitude to the United States and Canadian Academy of Pathology (USCAP) for recognizing the abstract of this study with Stowell-Orbison Certificate of Merit during the USCAP 112th Annual Meeting in New Orleans, LA, USA.

References

- 1 Cibas ES, Ali SZ & NCI Thyroid FNA State of the Science Conference. The Bethesda system for reporting thyroid cytopathology. *American Journal of Clinical Pathology* 2009 **132** 658–665. (<https://doi.org/10.1309/AJCPHLMW13JY4LA>)
- 2 Wang CC, Friedman L, Kennedy GC, Wang H, Kebebew E, Steward DL, Zeiger MA, Westra WH, Wang Y, Khanafshar E, *et al.* A large multicenter correlation study of thyroid nodule cytopathology and histopathology. *Thyroid* 2011 **21** 243–251. (<https://doi.org/10.1089/thy.2010.0243>)
- 3 American Thyroid Association Guidelines Taskforce on Thyroid N, Differentiated Thyroid C, Cooper DS, Doherty GM, Haugen BR, Kloos RT, Lee SL, Mandel SJ, Mazzaferri EL, McIver B, *et al.* Revised American Thyroid Association management guidelines for patients with thyroid nodules and differentiated thyroid cancer. *Thyroid* 2009 **19** 1167–1214. (<https://doi.org/10.1089/thy.2009.0110>)
- 4 Cavallo A, Johnson DN, White MG, Siddiqui S, Antic T, Mathew M, Grogan RH, Angelos P, Kaplan EL & Cipriani NA. Thyroid nodule size at ultrasound as a predictor of malignancy and final pathologic size. *Thyroid* 2017 **27** 641–650. (<https://doi.org/10.1089/thy.2016.0336>)
- 5 Flanagan MB, Ohori NP, Carty SE & Hunt JL. Repeat thyroid nodule fine-needle aspiration in patients with initial benign cytologic results. *American Journal of Clinical Pathology* 2006 **125** 698–702. (<https://doi.org/10.1309/4AXL-DMN1-JRPM-TX5P>)
- 6 Doubi A, Alrayes NS, Alqubaisi AK & Al-Dhahri SF. The value of repeating fine-needle aspiration for thyroid nodules. *Annals of Saudi Medicine* 2021 **41** 36–42. (<https://doi.org/10.5144/0256-4947.2021.36>)

- 7 Haugen BR, Alexander EK, Bible KC, Doherty GM, Mandel SJ, Nikiforov YE, Pacini F, Randolph GW, Sawka AM, Schlumberger M, *et al.* 2015 American Thyroid Association management guidelines for adult patients with thyroid nodules and differentiated thyroid cancer: the American Thyroid Association guidelines task force on thyroid nodules and differentiated thyroid cancer. *Thyroid* 2016 **26** 1–133. (<https://doi.org/10.1089/thy.2015.0020>)
- 8 Mitchell J & Parangi S. The thyroid incidentaloma: an increasingly frequent consequence of radiologic imaging. *Seminars in Ultrasound, CT, and MR* 2005 **26** 37–46. (<https://doi.org/10.1053/j.sult.2004.10.004>)
- 9 Brito JP, Gionfriddo MR, Al Nofal A, Boehmer KR, Leppin AL, Reading C, Callstrom M, Elraiyah TA, Prokop LJ, Stan MN, *et al.* The accuracy of thyroid nodule ultrasound to predict thyroid cancer: systematic review and meta-analysis. *Journal of Clinical Endocrinology and Metabolism* 2014 **99** 1253–1263. (<https://doi.org/10.1210/jc.2013-2928>)
- 10 Guth S, Theune U, Aberle J, Galach A & Bamberger CM. Very high prevalence of thyroid nodules detected by high frequency (13 MHz) ultrasound examination. *European Journal of Clinical Investigation* 2009 **39** 699–706. (<https://doi.org/10.1111/j.1365-2362.2009.02162.x>)
- 11 Jin J & McHenry CR. Thyroid incidentaloma. *Best Practice and Research. Clinical Endocrinology and Metabolism* 2012 **26** 83–96. (<https://doi.org/10.1016/j.beem.2011.06.004>)
- 12 Adas M, Adas G, Koc B & Ozulker F. Incidental thyroid lesions on FDG-PET/CT: a prevalence study and proposition of management. *Minerva Endocrinologica* 2015 **40** 169–175.
- 13 Hegedus L. Clinical practice. The thyroid nodule. *New England Journal of Medicine* 2004 **351** 1764–1771. (<https://doi.org/10.1056/NEJMcp031436>)
- 14 Cibas ES & Ali SZ. The 2017 Bethesda system for reporting thyroid cytopathology. *Thyroid* 2017 **27** 1341–1346. (<https://doi.org/10.1089/thy.2017.0500>)
- 15 Mohammadi M, Betel C, Burton KR, Higgins KM, Ghorab Z & Halperin IJ. Follow-up of benign thyroid nodules-can we do less? *Canadian Association of Radiologists Journal* 2019 **70** 62–67. (<https://doi.org/10.1016/j.carj.2018.10.001>)
- 16 Ajmal S, Rapoport S, Ramirez Battle H & Mazzaglia PJ. The natural history of the benign thyroid nodule: what is the appropriate follow-up strategy? *Journal of the American College of Surgeons* 2015 **220** 987–992. (<https://doi.org/10.1016/j.jamcollsurg.2014.12.010>)
- 17 Medici M, Liu X, Kwong N, Angell TE, Marqusee E, Kim MI & Alexander EK. Long- versus short-interval follow-up of cytologically benign thyroid nodules: a prospective cohort study. *BMC Medicine* 2016 **14** 11. (<https://doi.org/10.1186/s12916-016-0554-1>)
- 18 Oertel YC, Miyahara-Felipe L, Mendoza MG & Yu K. Value of repeated fine needle aspirations of the thyroid: an analysis of over ten thousand FNAs. *Thyroid* 2007 **17** 1061–1066. (<https://doi.org/10.1089/thy.2007.0159>)
- 19 Rossi ED, Pantanowitz L & Faquin WC. The Role of Molecular Testing for the Indeterminate Thyroid FNA. *Genes* 2019 **10** 736. (<https://doi.org/10.3390/genes10100736>)
- 20 Liu X, Bishop J, Shan Y, Pai S, Liu D, Murugan AK, Sun H, El-Naggar AK & Xing M. Highly prevalent tert promoter mutations in aggressive thyroid cancers. *Endocrine-Related Cancer* 2013 **20** 603–610. (<https://doi.org/10.1530/ERC-13-0210>)
- 21 Melo M, da Rocha AG, Vinagre J, Sobrinho-Simoes M & Soares P. Coexistence of tert promoter and BRAF mutations in papillary thyroid carcinoma: added value in patient prognosis? *Journal of Clinical Oncology* 2015 **33** 667–668. (<https://doi.org/10.1200/JCO.2014.59.4614>)
- 22 Yang J, Gong Y, Yan S, Chen H, Qin S & Gong R. Association between tert promoter mutations and clinical behaviors in differentiated thyroid carcinoma: a systematic review and meta-analysis. *Endocrine* 2020 **67** 44–57. (<https://doi.org/10.1007/s12020-019-02117-2>)
- 23 Marotta V, Bifulco M & Vitale M. Significance of RAS mutations in thyroid benign nodules and non-medullary thyroid cancer. *Cancers* 2021 **13**. (<https://doi.org/10.3390/cancers13153785>)
- 24 Topf MC, Wang ZX, Tuluc M & Pribitkin EA. TERT, HRAS, and EIF1AX Mutations in a Patient with Follicular Adenoma. *Thyroid* 2018 **28** 815–817. (<https://doi.org/10.1089/thy.2017.0504>)
- 25 Heller M, Zanoocco K, Zydowicz S, Elaraj D, Nayar R & Sturgeon C. Cost-effectiveness analysis of repeat fine-needle aspiration for thyroid biopsies read as atypia of undetermined significance. *Surgery* 2012 **152** 423–430. (<https://doi.org/10.1016/j.surg.2012.05.038>)
- 26 Hoang JK, Middleton WD, Farjat AE, Langer JE, Reading CC, Teefey SA, Abinanti N, Boschini FJ, Bronner AJ, Dahiya N, *et al.* Reduction in thyroid nodule biopsies and improved accuracy with American College of Radiology thyroid imaging reporting and data system. *Radiology* 2018 **287** 185–193. (<https://doi.org/10.1148/radiol.2018172572>)
- 27 Hammer MM & Kong CY. Cost-effectiveness of follow-up ultrasound for incidental thyroid nodules on CT. *AJR. American Journal of Roentgenology* 2022 **218** 615–622. (<https://doi.org/10.2214/AJR.21.26786>)